

# Circulation

JOURNAL OF THE AMERICAN HEART ASSOCIATION



## **A Sector Scanner for Real Time Two-Dimensional Echocardiography**

JAMES M. GRIFFITH and WALTER L. HENRY

*Circulation* 1974;49:1147-1152

Circulation is published by the American Heart Association, 7272 Greenville Avenue, Dallas, TX 75214

Copyright © 1974 American Heart Association. All rights reserved. Print ISSN: 0009-7322. Online ISSN: 1524-4539

The online version of this article, along with updated information and services, is located on the World Wide Web at:

<http://circ.ahajournals.org>

Subscriptions: Information about subscribing to *Circulation* is online at  
<http://circ.ahajournals.org/subscriptions/>

Permissions: Permissions & Rights Desk, Lippincott Williams & Wilkins, 351 West Camden Street, Baltimore, MD 21202-2436. Phone 410-5280-4050. Fax: 410-528-8550. Email:  
[journalpermissions@lww.com](mailto:journalpermissions@lww.com)

Reprints: Information about reprints can be found online at  
<http://www.lww.com/static/html/reprints.html>

# A Sector Scanner for Real Time Two-Dimensional Echocardiography

By JAMES M. GRIFFITH, M.S.E.E. AND WALTER L. HENRY, M.D.

## SUMMARY

During the past several years one-dimensional pulse-echo ultrasound techniques have proven extremely useful in cardiac diagnosis. A one-dimensional system, however, only visualizes structures lying along a single straight line. The spatial relationships of the various cardiac structures are therefore not so easily defined as with two-dimensional systems which display the heart by constructing a plane image composed of many straight lines. We have developed a sector scanning system for obtaining two-dimensional echocardiograms in real time using ultrasonic pulse-echo techniques. Images are produced by angling rapidly a single transducer through a 30-degree sector from a fixed spot (between ribs) on the patient's chest. Thirty complete sectors (or frames) are produced per second. The use of a large diameter transducer ensures that signal strength is good and cardiac structures, including endocardium, can be visualized. Other advantages include high transducer sensitivity, real time imaging and easy visualization of various regions of the heart. Experience with more than 100 patients indicates that diagnostic quality two-dimensional echocardiograms can be readily obtained in essentially the same patients from whom one-dimensional echocardiograms are recorded and can usually be performed in less time.

## Additional Indexing Words:

Cardiac cross-sections  
Ultrasonic imaging

Noninvasive technique

Pulse-echo ultrasound

**D**URING THE PAST SEVERAL YEARS one-dimensional pulse-echo ultrasound techniques have proven extremely useful in cardiac diagnosis.<sup>1-14</sup> A one-dimensional system, however, only measures distances to structures lying along a single straight line. Cardiac anatomy is therefore not so easily defined as with two-dimensional systems, which simultaneously measure distances along many straight lines comprising a plane. Several systems<sup>15-20</sup> have been described for obtaining two-dimensional echocardiograms. None, however, has combined the advantages of a high sensitivity, narrow beam transducer, real time imaging, and a simple method for controlling the section of the heart being viewed. This paper describes the design of a system that includes these features. Subsequent publications will describe specific clinical applications.<sup>21</sup>

## System Design

The scanning system uses the pulse-echo technique with a single ultrasonic transducer or probe (Aerotech 2.25 MHz, 12 mm diameter) and receiver (Ekoline 20A), the same types

typically used for one-dimensional applications. It has three major components: (a) hand-held scanner, (b) video display and (c) video recorder (fig. 1).

## Hand-Held Scanner

The hand-held scanner consists of the ultrasound transducer (which both transmits and receives ultrasonic signals), an angle indicator, and a small feedback-regulated DC motor. The transducer reciprocates continuously through a 30-degree sector at a rate of 15 cycles/sec. Each complete cycle results in the generation of two separate 30-degree sectors (i.e., one sector is visualized as the transducer moves from left to right and another from right to left), providing 30 separate frames (or sectors) per second. In addition, the transmitter is pulsed at a rate of 2 KHz; therefore each frame consists of 66 separate ultrasound signal lines. The angular motion is produced by a small DC motor connected to the transducer via a crank and lever system (figs. 2 and 3).

The angular position of the probe is monitored continuously by the angle indicator (a rotary variable differential transformer) attached to the motor through a mechanical linkage identical to that driving the transducer. The electrical signal generated by the indicator therefore is always proportional to the transducer orientation. A tachometer-feedback system regulates motor speed so that the frame rate does not change appreciably with variations in contact force between the transducer and patient.

The use of a 12 mm diameter ultrasound transducer results in high quality images; low intensity echoes, e.g., from endocardium, can be detected easily. In addition, the probe is not angled faster than 1.4 degrees/msec and therefore the transducer angle changes no more than 0.7 degrees during a transmit and receive cycle (a transmit and

From the Biomedical Engineering and Instrumentation Branch, Division of Research Services and Cardiology Branch, National Heart and Lung Institute, Bethesda, Maryland.

Address for reprints: Mr. James M. Griffith, Building 13, Room 3W13, National Institutes of Health, Bethesda, Maryland 20014.

Received January 18, 1974; revision accepted for publication February 26, 1974.

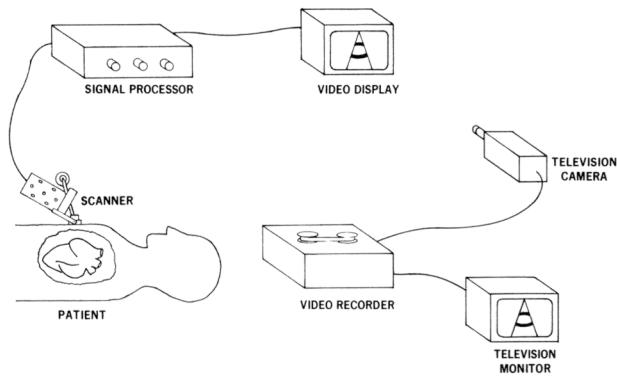


Figure 1

Diagrammatic representation of the sector scanning system. The ultrasound transducer reciprocates through a 30-degree sector of the heart. Signals from the scanner are processed and fed to the video display so that the cross-section of the heart is visualized. The television camera records the image on video tape. The image is subsequently viewed on the television display monitor.

receive cycle is 0.5 msec). Since a 12 mm probe has a 6 degree beam width, there is no significant signal loss or distortion caused by the scanning motion; and resolution, axially and radially, is essentially the same as in the typical one-dimensional system. Moreover, the sector generation rate of 30/sec is fast enough to prevent flicker in the image.

#### Video Display

The echoes received from the scanned sector are electronically processed and displayed on a cathode ray tube. Patterns are produced by electronically synchronizing the cathode ray tube beam and the probe angle so that the position of the beam is always proportional to the position from which the echoes are received. The echo signal amplitude is used to modulate beam intensity, thus generating the image (fig. 4). For example, a pulse is emitted and received along line  $A_1$ . The angle indicator generates an electrical signal proportional to angle  $\alpha$ , which is fed into a circuit that reproduces the received ultrasound signal on the video display along line  $B_1$  at an angle  $\beta$ . The circuit has been designed so that angle  $\alpha$  equals angle  $\beta$ . By angling the probe from  $A_1$  to  $A_{66}$  and simultaneously generating lines  $B_1$  to  $B_{66}$  on the video display, a complete 30-degree sector image (or frame) is produced.

The crank and lever arrangement angles the transducer in

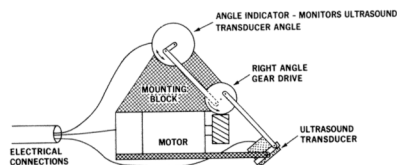


Figure 2

Diagrammatic representation of the hand-held scanner. A tachometer-feedback regulated DC motor drives a crank and lever system which angles the ultrasound transducer in a reciprocating manner through a 30-degree sector. The angle indicator is driven simultaneously by an identical mechanical linkage and generates an electrical signal proportional to the transducer angle.

a sinusoidal fashion, e.g., the beam moves most rapidly through the sector's center and then slower at the sides. Although a more complex drive system might make the line density more even, the present scan pattern does not require special signal processing for the side portions.

#### Video Recording

Each ultrasonic sector or frame is composed of 66 separate lines. An ideal recording system would provide some means of summing each set of 66 lines as a separate frame. This could be done by using a movie camera like the Milliken model DBM-16 which has a film pull-down time of about one msec. Since the pull-down could be externally synchronized to occur at the edge of a frame, only two of the 66 lines would be lost. A camera of this type, however, is expensive and not easily available. A closed circuit television system, utilizing a television camera, television monitor and video tape recorder was therefore used (fig. 1). In our system, the camera is focused on the video display and its output is recorded on video tape. At the present stage of development, the video recorder fields (60/sec) are not synchronized with the scan frames (30/sec). In practice, this difference in frame rate and lack of synchronization is not serious because of both the decay time in the video display and the inherent integration of the television camera. Although a system of this type does not record exactly one ultrasonic frame on one video frame, it does allow images of fast moving structures, like the mitral valve, to be recorded accurately. A significant advantage of the video tape system

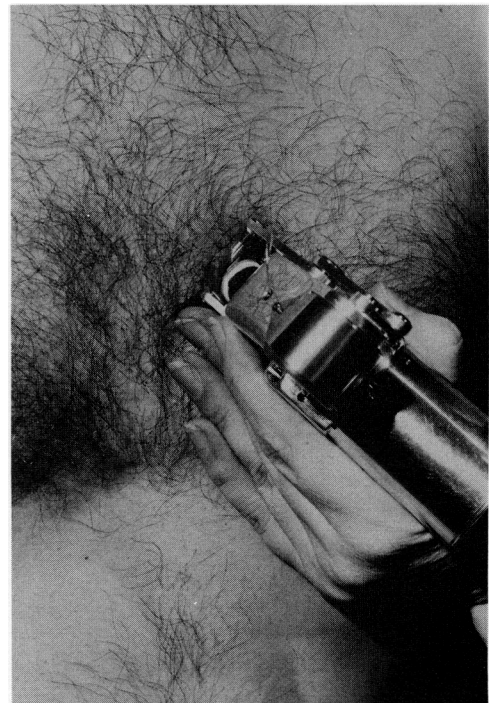


Figure 3

Photograph showing scanner's actual shape and positioning on the chest. Patient is supine with head at the top of the picture; the scanner is oriented to scan along the left ventricular long axis. Although patients are aware of the transducer's rocking motion, they do not find it unpleasant.

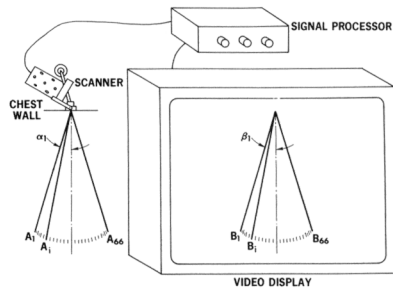


Figure 4

Lines in the two-dimensional image are generated sequentially. When the transducer is directed along line  $A_1$ , the signal processor generates line  $B_1$  on the video display. As the transducer is rotated through the 30-degree sector to line  $A_{66}$  the display line is simultaneously swept through the sector to line  $B_{66}$ .

over film is that data are available for instant replay and analysis; slow motion and stop frame play-back are employed. In addition, analog channels are available for simultaneously recording ECG, pressures, blood flow, or voice.

Results

Two images, shown in figures 5 and 6, were obtained with the sector scanner oriented parallel to the




Figure 5

Diastolic frame obtained by scanning a normal heart parallel to the left ventricular long axis shows the closed aortic valve and open mitral valve. The septum is seen to narrow as it joins the aorta. AML = anterior mitral leaflet; AO = aorta; AoV = aortic valve; LA = left atrium; PM = papillary muscle; PML = posterior mitral leaflet; PW = posterior wall; RV = right ventricle; S = ventricular septum.

left ventricular long axis in a normal subject. The scanner was directed so that both the aortic and mitral valves were seen simultaneously. Figure 5 is one of the frames obtained during diastole which shows the aortic valve closed; the mitral valve open. The anterior leaflet is near the ventricular septum; the posterior leaflet is adjacent to the posterior left ventricular wall. The picture in figure 6 is one of the frames obtained during systole; the aortic valve is open and the mitral valve is closed. The head of the papillary muscles, the apposed mitral leaflets, and the mitral valve ring are clearly visible. In figures 7, 8, and 9 the scanner was rotated 90° so that the scanned sector is perpendicular to the left ventricular long axis. The cross-sections show the heart as if it were viewed from the apex; that is, the patient's chest is at the top and his left side is at the right. Figure 7 images the left ventricle during late systole at the level of the papillary muscles. The septum, papillary muscles, and posterior wall are demonstrated. Figure 8 was obtained by scanning another normal subject at a slightly higher level, thus displaying septum, anterior and posterior mitral leaflets, and posterior wall. Finally, figure 9 was obtained at the level of the aortic root. The aorta and left atrium are in cross-section, the aortic valve is closed, and the right ventricular outflow tract curves obliquely over the aorta.

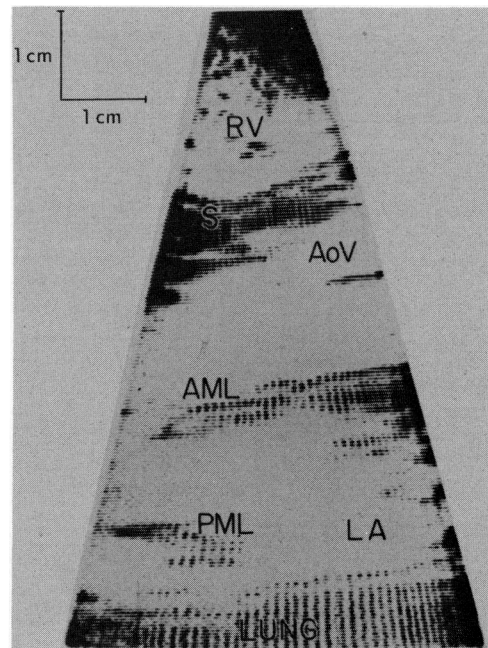


Figure 6

Systolic frame from the same subject obtained by scanning parallel to the left ventricular long axis shows the open aortic valve and closed mitral valve.

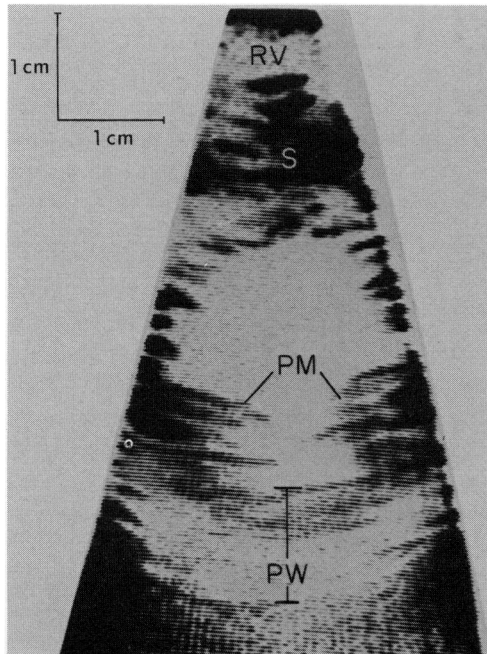


Figure 7

Image obtained at end systole by scanning a normal heart perpendicular to the left ventricular long axis at the level of the papillary muscles. The septum, ventricular cavity, papillary muscles, and posterior wall are shown. The posterior wall thickness was verified by observing several cardiac cycles and adjusting the receiver damping.

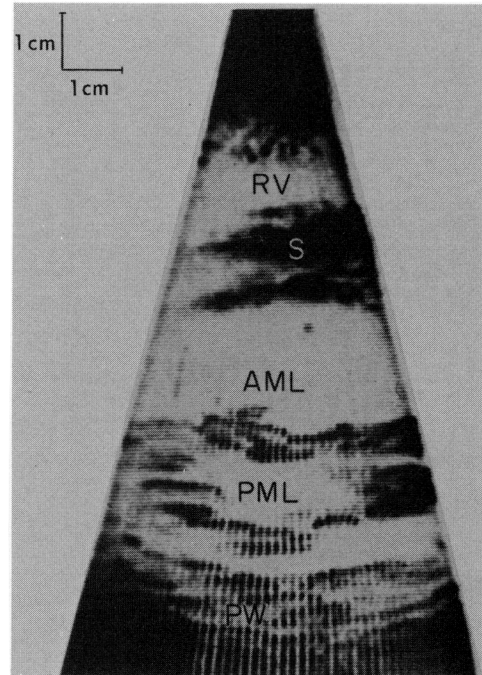


Figure 8

Image obtained at mid-diastole by scanning another normal subject perpendicular to the left ventricular long axis at the level of the mitral leaflets.

Experience with over 100 subjects, age two months to sixty years, has not shown any particular group more difficult to study than another.

#### Discussion

The desirability of viewing the heart ultrasonically in two-dimensions has been recognized for some time. The system described meets the requirements of a scanner for clinical use. Examination is done in real time, using a hand-held scanner; an operator watches the video display and simultaneously adjusts the scanner position until the heart section to be viewed is displayed. The section can be chosen at any orientation relative to the heart's major and minor axes. By slowly altering the scanner orientation, it is possible to visualize specific structures and accurately determine their relationships to other cardiac structures. Moreover, the 30-per-second frame rate prevents flicker in the display, an important operator consideration, and allows visualization of fast moving cardiac structures. Acoustic coupling between the scanner and the chest is provided by a layer of transmission gel.

The tilting mirror system<sup>15</sup> and the time-gated, non-real time systems<sup>16-19</sup> have been useful but are rather

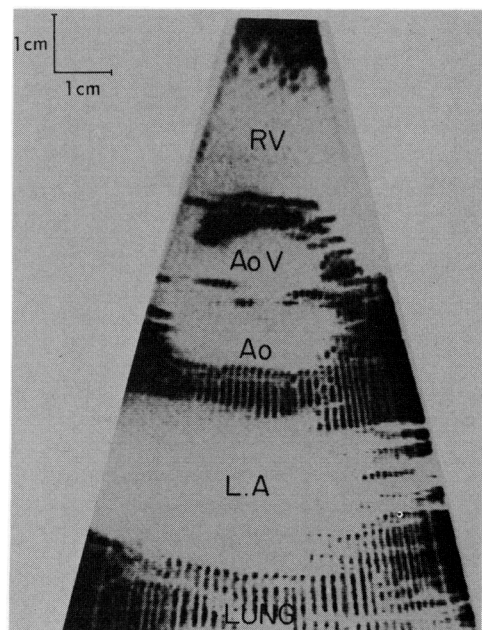


Figure 9

Diastolic frame obtained by scanning a normal heart perpendicular to the left ventricular long axis at the level of the origin of the great arteries. The aortic leaflets are closed and the right ventricular out-flow tract is seen to curve obliquely around the aorta.

cumbersome and time-consuming for routine clinical use. For example, 50 or more separate cardiac cycles are used to compose one frame in the time-gated systems. Further, it may be necessary to repeat this procedure several times in order to visualize the region of interest or to obtain frames from a different phase of the cardiac cycle. Obviously, patients with atrial fibrillation are particularly difficult to study with this method. Since our system allows visualization of 30 frames per second, the problems of a nonreal time system are overcome and observations can be made easily and rapidly.

The multi-element ultrasound system<sup>20</sup> is similar to our system in that it generates real time images and is quite simple to use. There are, however, several differences between the two. First, the sector scanner described in this paper employs a larger transducer with concomitant greater sensitivity and resolution than the small transducers used in the multi-element equipment. Second, our system generates 30 complete frames per second of 66 ultrasound data lines each, whereas the multi-element system generates 160 frames per second of 20 lines each. Clinical use thus far suggests that the increased number of data lines produces images of improved detail without significantly impairing the capability for visualizing the motion of rapidly moving cardiac structures. Since our system is designed to function from a small spot on the chest (between ribs), the signal absorption and distortion that may occur when a transducer is placed over ribs or lung are minimized. As with a one-dimensional system, however, about 10 percent of the patients cannot be studied because of chest configuration or lung location. The increased sensitivity, increased number of data lines per frame and diminished signal distortion have been gained, however, with some sacrifice. For instance, the region of the heart being visualized decreases as one nears the chest wall. The multi-element system allows a much greater area to be visualized near the chest wall and as a result may produce better definition of the right ventricle. The area limitation of the sector scanning system, however, does not affect left ventricular image quality. In this region of the heart the increased sensitivity and increased number of data lines per frame of the sector scanning system provide images of improved definition.

Although our system is at an early stage of development, we believe that two-dimensional echocardiography will prove to be an extremely useful tool for cardiac diagnosis. It allows a large portion of the left ventricle to be visualized safely and painlessly without the discomfort and risk associated with cardiac catheterization. Since radiopaque dye is not used, the

arrhythmias and depression of myocardial contractility that commonly occur following the injection of dye are not present. Moreover, it is possible to visualize an unlimited number of consecutive cardiac cycles, as compared to the limitation to five or six consecutive cycles for conventional angiography. Another feature is the capability of visualizing minor axis cross-sections of the heart at several levels. For example, the cross-section of the heart at the level of the great vessels (fig. 9) clearly demonstrates the normal relationship of the great vessels, i.e., the right ventricular outflow tract is seen in longitudinal view to curve anterior to the cross-sectioned aorta (viewed as a circle.) Experience thus far has demonstrated that this image is characteristic of normally related great vessels and that the abnormal anatomy associated with such congenital malformations as transposition complexes, pulmonary atresia, and truncus arteriosus can be visualized clearly.<sup>21</sup> If the heart is cross-sectioned at a lower level (fig. 8), the complete mitral valve orifice can be seen. Cross-sectioning the left ventricle below the mitral leaflets enables viewing and assessment of papillary muscle architecture (fig. 7). Experience with more than 100 patients indicates that diagnostic quality, two-dimensional echocardiograms can be painlessly obtained in essentially the same patients from whom one-dimensional echocardiograms are recorded. Moreover, two dimensional studies can usually be performed in less time. We are presently exploring other research and clinical applications that are made feasible by this technique.

#### Acknowledgment

The authors thank Mr. John A. Clark, Biomedical Engineering and Instrumentation Branch, DRS, for his valued suggestions and assistance in constructing the scanner.

#### References

1. FEIGENBAUM H: Echocardiography. Philadelphia, Lea and Febiger, 1972
2. FEIGENBAUM H: Clinical applications of echocardiography. *Prog Cardiovasc Dis* 14: 531, 1972
3. EDLER I, HERTZ CH: Ultrasound cardiogram in mitral valve disease. *Acta Chir Scand* 111: 230, 1956
4. JOYNER CR, REID JM, BOND JP: Reflected ultrasound in the assessment of mitral valve disease. *Circulation* 27: 503, 1963
5. GRAMIAK R, SHAH PM: Echocardiography of the normal and diseased aortic valve. *Radiology* 96: 1, 1970
6. POPP RL, HARRISON DC: Ultrasound in the diagnosis and evaluation of therapy of idiopathic hypertrophic subaortic stenosis. *Circulation* 40: 905, 1969
7. ZAKY A, NASSER WK, FEIGENBAUM H: Study of mitral valve action recorded by reflected ultrasound and its application in the diagnosis of mitral stenosis. *Circulation* 37: 789, 1968
8. POPP RL, HARRISON DC: Ultrasonic cardiac echocardiography for determining stroke volume and valvular regurgitation. *Circulation* 41: 493, 1970



9. POMBO JF, TROY BL, RUSSELL RO JR: Left ventricular volumes and ejection fraction by echocardiography. *Circulation* **43**: 480, 1971
10. FORTUIN NJ, HOOD WP JR, CRAIGE E: Evaluation of left ventricular function by echocardiography. *Circulation* **46**: 26, 1972
11. COOPER RH, O'ROURKE RA, KARLINER JS, PETERSON KL, LEOPOLD GR: Comparison of ultrasound and cineangiographic measurements of the mean rate of circumferential fiber shortening in man. *Circulation* **46**: 914, 1972
12. PARASKOS JA, GROSSMAN W, SALTZ S, DALEN JE, DEXTER L: A non-invasive technique for the determination of velocity of circumferential fiber shortening in man. *Circ Res* **29**: 610, 1971
13. HENRY WL, CLARK CE, EPSTEIN SE: Asymmetric septal hypertrophy: Echocardiographic identification of the pathognomonic anatomic abnormality of IHSS. *Circulation* **47**: 225, 1973
14. HENRY WL, CLARK CE, GLANCY DL, EPSTEIN SE: Echocardiographic measurement of the left ventricular out-flow gradient in idiopathic hypertrophic subaortic stenosis. *N Engl J Med* **288**: 989, 1973
15. ASBERG A: Ultrasonic cinematography of the living heart. *Ultrasonics* **6**: 113, 1967
16. EBINA T, OKA S, TANKA M, KOSAKA S, TERASAWA Y, UNNO K, KIKUCHI Y, UCHIDA R: The ultrasono-tomography for the heart and great vessels in living human subjects by means of the ultrasonic reflection technique. *Jap Heart J* **8**: 331, 1967
17. KING DL, STEEG CN, ELLIS K: Demonstration of transposition of the great arteries by cardiac ultrasonography. *Radiology* **107**: 181, 1973
18. KING DL: Cardiac ultrasonography. *Circulation* **47**: 843, 1973
19. GRAMIAK R, WAAG R, SIMON W: Cine ultrasound cardiography. *Radiology* **107**: 175, 1973
20. BOM N, LANCEE CT, ZWIETEN G, KLOSTER FE, ROELANDT J: Multiscan echocardiography. I. Technical description. *Circulation* **48**: 1066, 1973
21. HENRY WL, MARON BJ, GRIFFITH JM, EPSTEIN SE: The differential diagnosis of anomalies of the great vessels by real-time, two-dimensional echocardiography. (abstr) *Am J Cardiol* **33**: 143, 1974